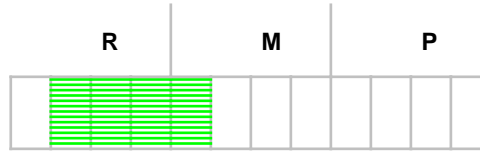




Owen Block Analysis

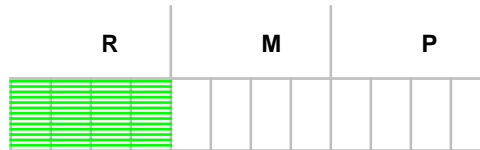
Doctor: James Mangutz , Patient: Unknown , Age: 12 , Gender: Male , Date: 07-Oct-2003

1. Maxillary Skeletal



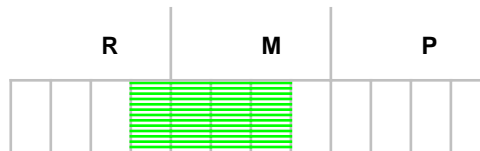
SNA	80<82<84	76	2 RETROGNATHIC
N-VERT-A mm	-2<0<2	-6	2 RETROGNATHIC
NASOLABIAL ANGLE	113>105>97	109	0 MESIOGNATHIC
U / LIP - SUBNASALE	1>2>3	4	1 PROGNATHIC

2. Maxillary Dental



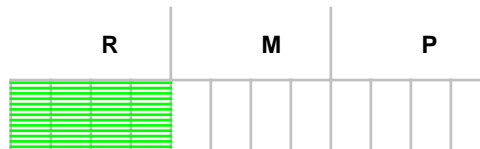
U/1 TO SN	100<104<108	88	3 RETROCLINED
U/1 TO PAL/PL	105<110<115	106	0 MESIOCLINED
U/1 TO NA(DEG)	18<22<26	12	2 RETROCLINED
U/1 TO NA(mm)	2<4<6	-2	2 RETROCLINED
U/LIP DRAPE	92<97<102	87	1 RETROCLINED

3. Mandibular Dental



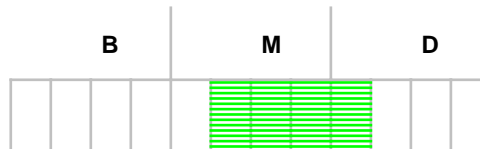
IMPA	90<95<100	93	0 MESIOCLINED
LOWER I TO NB(DEG)	21<25<29	23	0 MESIOCLINED
LOWER I TO NB(mm)	2<4<6	3	0 MESIOCLINED
LOWER I TO A/P(mm)	0<2<4	-2	1 RETROCLINED
HALF STEINER (mm)	-5<0<5	-1	0 MESIOCLINED

4. Mandibular Skeletal



SNB ANGLE	78<80<82	70	4 RETROGNATHIC
FACIAL ANGLE(DOWNS)	86<89<92	80	2 RETROGNATHIC
NA VERT TO PO (mm)	-9<-6<-3	-23	5 RETROGNATHIC
E ANGLE	68<72<76	62	2 RETROGNATHIC

5. Vertical



GOGN-SN	28<32<36	40	1 DOLICHIFACIAL
OM ANGLE	15<20<25	21	0 MESIOFACIAL
Y AXIS	64<67<70	74	2 DOLICHIFACIAL
JARABAK S-GO:N-ME	62<64<66 %	60	1 BRACHYFACIAL
ANT FACE HT(N-ANS-ME)	55% +-2	51	1 BRACHYFACIAL