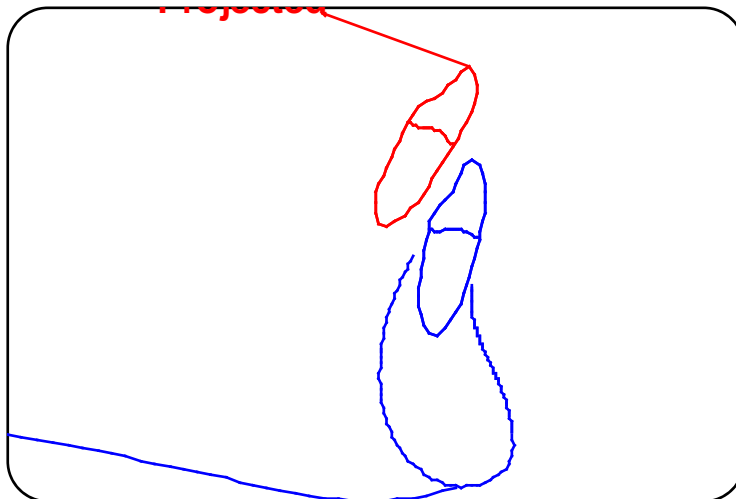



V.T.O ANALYSIS



Doctor: James Mangutz , Patient: Unknown , Age: 12 , Gender: Male , Date: 07-Oct-2003

CEPH DISC(*2) 2 MM



V.T.O ANALYSIS OVERLAY



Doctor: James Mangutz , Patient: Unknown , Age: 12 , Gender: Male , Date: 07-Oct-2003

